Case Report

iMedPub Journals
www.imedpub.com

Journal of Reproductive Endocrinology & Infertility
ISSN 2476-2008

2021
Vol. 6 No. 6: 31

DOI: 10.36648/2476-2008.6.6.31

Congenital Absence of the Endometrium: a Rare Cause of Primary Amenorrhea

Zelalem Ayichew*

Department of Obstetrics and Gynecology, University of Gondar, Gondar, Ethiopia

***Corresponding author:**
Zelalem Ayichew

zelalem538@yahoo.com

Department of Obstetrics and Gynecology, University of Gondar, Gondar, Ethiopia

Citation: Ayichew Z (2021) Congenital Absence of the Endometrium: a Rare Cause of Primary Amenorrhea. J Rep Endo Infert. Vol.6 No.6: 31.

Abstract

Primary amenorrhea is failure to menstruate by the age of 16 years irrespective of secondary sexual characteristics. It is mostly caused by premature ovarian failure secondary to gonadal digenesis of which Turner syndrome is the commonest. Congenital problems of the reproductive tract especially mullerian agenesis are another important cause. Isolated congenital absence of the endometrium is a very rare cause of primary amenorrhea with only two case reports so far. Here I present a 25 years old woman who presented with failure to see menstruate but with well-developed secondary sexual characteristics where congenital absence of the endometrium was found as the cause of her amenorrhea. So in women with primary amenorrhea in the presence of secondary sexual characteristics and uterus, with absence of endometrial stripe on transvaginal Sonography and patent uterine cavity on uterine sounding, congenital absence of the endometrium should be entertained as a cause of primary amenorrhea.

Keywords: Primary amenorrhea; Causes of primary amenorrhea; Congenitally absent endometrium

Received: October 16, 2021, **Accepted:** November 22, 2021, **Published:** November 29, 2021

Introduction

Amenorrhea is the absence or abnormal cessation of the menses. Primary and secondary amenorrhea describes the occurrence of amenorrhea before and after menarche, respectively. Primary amenorrhea: is defined as: absence of menses by 14 years of age in the absence of growth or development of secondary sexual characteristics or absence of menses by 16 years of age regardless of the presence of normal growth and development including secondary sexual characteristics [1]. It may be caused by problems in the outflow tract, ovaries, hypothalamus or anterior pituitary. Gonadal dysgenesis which includes turner syndrome is the most common cause of delayed puberty and primary amenorrhea.

Congenital female reproductive tract anomalies of which Mullerian agenesis which patients with this problem have absent uterus and vagina is another cause of primary amenorrhea. In such cases ovaries are normally well developed and ovulation occurs normally in these girls [2]. Congenital absence of the endometrium which is absence of the glandular mucous membrane lining of the uterine cavity that is hormonally responsive during the estrous/ menstrual cycle and during pregnancy is a very rare condition with only two case reports published online. The uterus could be with cavity or without [3,4]. Here I present a 28 years old woman diagnosed with primary amenorrhea secondary to congenital absence of the endometrium.

Case History

28 years old lady presented to Gondar university hospital complaining failure to menstruate. She was also married 5 years back but failed to conceive. She had no problem of sexual intercourse. She has never used contraception. Her peer friends are menstruating and have children. She has 2 sisters but both are yet below age of 13 years. She noticed development of her breasts and pubic hair at the age of 14 years. She has monthly cyclic lower abdominal discomfort and breast pain. A year back she was seen at nearby health institution and was prescribed with progesterone but there was no withdrawal bleeding. She was then given combined oral contraceptive pills for 3 months and there was no uterine bleeding. She has no head ache, visual disturbance or galactorrhea. She has no history of uterine instrumentation, history of pelvic infection or tuberculosis. She had no history of chronic medical illnesses.

Physical Examination

She is apparently healthy looking with normal body makeup and stature. The vital signs are within normal range. Her weight is 60 kg and height is 168 cm. She has female type hair distribution over her head. No anterior neck mass. Breasts are well developed symmetrical and pendulous.

She has normal female type external genitalia with female type pubic hair distribution of adult type. Vagina is 9 cm long with

normal cervix and cervical opening seen. Uterus is small with normal position. Uterine sound was inserted to check patency of the uterine cavity and was patent and measures 4 cm together with the cervical canal.

Laboratory

FSH = 8.3

Testosterone, Prolactin and Thyroid function tests are all in the normal range.

Results

Transvaginal ultrasound was done showing hypo plastic uterus measuring 2.5 cm by 2 cm. Cervical canal is seen but the endometrial strip is not visualized. Both ovaries are seen in their normal position with follicles. Both kidneys are in the normal position on Tran's abdominal ultrasound **(Figures 1, 2 and 3)**.

Hysteroscopy

Hysteroscopy was done under spinal anesthesia. The cervical canal is clearly seen and the hysteroscopy was advanced to pass the internal OS. A small patent uterine cavity with superficial vessels is seen. There were no adhesions and the right tubal Ostia are seen **(Figures 4 and 5)**.

Endometrial Biopsy

Endometrial biopsy was taken with hysteroscopy forceps but impossible to get sample so curettage was done and sent to histologic evaluation that showed only blood and no endometrial gland or stroma is seen.

Figure 1 Transvaginal u/s of uterus. Note that endometrial strip is not seen.

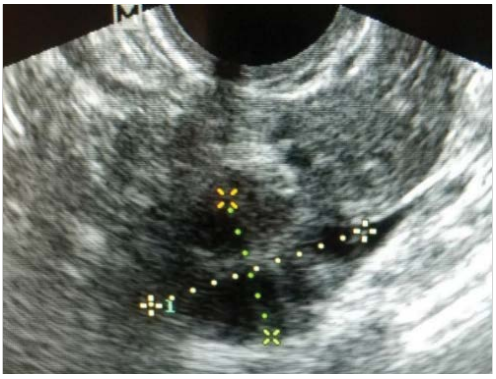

Figure 2 Right ovary measuring 2.7cm by 1.8 cm with follicles seen.

Figure 3 Left ovary measuring 1.87 cm by 1.68 cm with follicles seen.

Figure 4 Hysteroscopic view of the cervical canal till the internal os.

Figure 5 Hysteroscopic appearance of the uterine cavity with superficial vessels the tubal Ostia seen on right side.

Discussion

Primary amenorrhea is usually the result of a genetic or anatomic abnormality. From the most common etiologies of primary amenorrhea seen in a large case series, congenital anomalies of the reproductive tract i.e. Absence of the uterus, cervix and/or vagina, müllerian agenesis accounted for 15 percent and Transverse vaginal septum or imperforate hymen for 5 percent of the cases [3]. History, physical examination, and estimation of follicle stimulating hormone (FSH), thyroid stimulating hormone

(TSH), and prolactin will identify the most common causes of amenorrhea. When the physical examination is normal (the majority of cases), the initial investigations should exclude pregnancy and estimate FSH and prolactin concentrations. Congenital absence of the endometrium is an uncommon etiology for primary amenorrhea, and no visualization of the endometrial stripe on ultrasound imaging in association with primary amenorrhea should raise suspicion of this rare disorder in this case [4]. Endometrial absence is a differential diagnosis for primary amenorrhea; assessment of the uterine cavity and obtaining biopsy samples may help in diagnosis of suspected cases before they undergo assisted reproduction and can avoid unnecessary treatment [5].

Conclusion

In women with primary amenorrhea in the presence of secondary sexual characteristics and uterus with patent cavity, congenital absence of the endometrium should be entertained as a possible cause of primary amenorrhea. Endometrial biopsy should then be done to confirm the diagnosis.

References

1 Marc AF, Speroff L Amenorrhoea (2015) Clinical Gynecologic Endocrinology and Infertility 9th ed. Philadelphia: Wolter Kluwer (Replica Press):435-93.

2 Samal R, et al. (2017) Primary amenorrhea: a clinical review. Int J Reprod Contracept Obstet Gynecol 6(11):4748-4753.

3 Berker B, Taşkin S, Taşkin EA, (2008) Absence of endometrium as a cause of primary amenorrhea Fertile Steril. 89(3):1-3.

4 Simavli S, Abreu AP, Kwaan MR et al. (2016) Candidate gene analysis in a case of congenital absence of the endometrium. Fertil Res and Pract 2:3.

5 Reindollar RH, Byrd JR, McDonough PG (1981) Delayed sexual development: a study of 252 patients. Am J Obstet Gynecol 140:371.